


Bacterial wound infections leading to bacteraemia with *Vibrio vulnificus* and *Morganella morganii*; two unusual cases

Piyasiri DLB, Kirubaharan A, Nanayakkara IRS, Jayasekara JVGM, Galhenage MN, Sapukotana PM

Microbiology Unit, Teaching Hospital Karapitiya, Galle, Sri Lanka.

Correspondence: Dr. Bhagya Piyasiri
e-mail: bhagyapiyasiri@yahoo.co.uk
 <https://orcid.org/0000-0002-4660-311X>
Submitted on 23.01.2020 and accepted for publication on 01.03.2021

Case 1

A 84-years-old female diagnosed with cancer of the epiglottis admitted for a course of chemotherapy to Teaching Hospital Karapitiya (THK) in October 2019.

She was afebrile on admission, however, developed redness and swelling at the cannula site few days later. Next day, she fell in the hospital toilet and landed on the infected forearm. This toilet was a squatting type with water sourced from the local municipal council supply. There was no visible faecal contamination. Three days later, she developed severe infection with blister formation at the infected site with high fever spikes (Figure 1). There was no history of any local treatment to the site including ayurvedic preparations or salt.

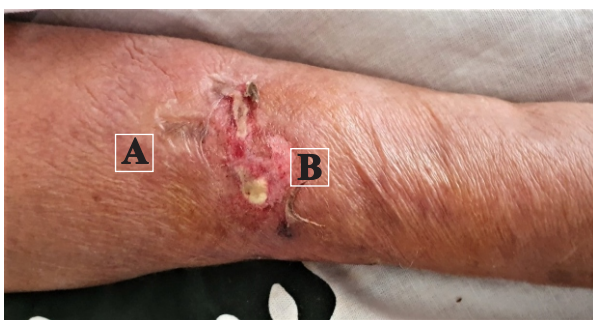

Figure 1: Wound Site A - Regressing blister, B - Ruptured blister

Her white cell count was $7.17 \times 10^3/\mu\text{L}$ with 95% neutrophils, while C-reactive protein (CRP) level was 204 mg/L. Intravenous (IV) ceftriaxone and clindamycin were started, but with poor response changed to IV imipenem 500 mg 6 hourly when the blood culture was flagged as positive for a Gram-negative organism. It grew a non-lactose fermenting, oxidase positive organism with *Shigella* pattern on Kligler's agar. Automatic identification machine VITEK[®] 2 COMPACT confirmed it as *Vibrio vulnificus* with sensitivity to all tested antibiotics including co-amoxiclav, cefotaxime, ciprofloxacin, gentamicin and imipenem. However, considering the immediate response following the administration of imipenem and her immunosuppression following chemotherapy, we continued imipenem with oral doxycycline 100mg 12 hourly for 14 days until the wound healed with normal CRP.

Vibrio vulnificus

Vibrio vulnificus is a halophilic organism, and found in seawater, oysters, crabs and plankton. It caused severe bullous wound infections at the site of skin breaches in the Asian tsunami survivors in 2004. Patients at risk of developing severe sepsis by *Vibrio vulnificus* are immunosuppressed, with co-morbidities; chronic liver disease (especially cirrhosis), end-stage renal disease, and haematopoietic disorders.

Interestingly, *Vibrio* species can also be one of the predominant flora not only in sea water, but also in sewage water (1). In this case, after inspection of the place and upon inquiring, we could not exclude the possibility of contamination of the toilet floor with sewage water and there was no any other identifiable source for this infection either. Due to immunosuppression and the contamination of the breached skin, she must have developed typical bullous infection and subsequent sepsis. There was another case known to the author; a middle-aged woman with diabetes admitted to the Sri Jayawardenapura General Hospital in November 2008 with orbital cellulitis following a fall into a sewage pit, had *Vibrio vulnificus* in her pus culture (unpublished). Therefore, the clinicians should consider *Vibrio* infection in bullous wounds and cellulitis developing after possible contamination with sewage water (1,2).

Case 2

A 60-years-old previously healthy male presented following an unidentified snakebite on his left foot in October 2019. On arrival to the local hospital, he went into respiratory arrest, ventilated, and was transferred to the intensive care unit, THK where he had anti-venom. Next day he developed a large necrotic area over the bite site and underwent wound debridement thrice subsequently.

On admission, his white cell count was $12.97 \times 10^3/\mu\text{L}$, but went-up to $19.7 \times 10^3/\mu\text{L}$ with CRP of 233 mg/L in 2 days. Blood culture collected on admission was flagged as positive after 20 hours incubation and yielded a non-lactose fermenting, oxidase negative Gram-negative bacterium, which was, identified as *Morganella morganii* by the VITEK® 2 COMPACT machine. The organism was sensitive for cefotaxime, gentamicin, amikacin, ciprofloxacin and meropenem. Pus aspirated from the wound was positive for the same isolate. He was treated with IV meropenem 1g 8 hourly for 14 days and IV amikacin 15 mg/kg daily for 7 days until CRP became normal, and wound became healthy undergoing successful skin grafting.

Morganella morganii

Morganella morganii is an uncommon cause of community acquired infections but can cause a range of infections including urinary tract infections, sepsis, pneumonia, wound infections, musculoskeletal infections, central nervous system infections, pericarditis, chorioamnionitis, endophthalmitis, empyema, spontaneous bacterial peritonitis and nosocomial outbreaks.

Enterobacteriaceae including *Morganella* are an important part of the mouth flora of snakes (3-5), because, the prey often defaecates inside snake's mouth. Hence, the same flora may contaminate the wounds of the humans following snakebite. Extensive tissue necrosis can be seen following some snakebites as hump-nosed viper in Sri Lanka and India (6, 7) and *Bothrops* (vipers) around the globe (4), which may be attributed to the faecal contamination of snake mouth.

Despite sensitivity, cephalosporines were avoided as *Morganella* has the potential to develop resistance during treatment. Considering the bacteraemia and the severity of the wound infection, a carbapenem with an aminoglycoside were chosen. Therefore, in snakebite wound infections it is always better to perform cultures and to cover faecal flora empirically with an antibiotic regime like co-amoxiclav plus an aminoglycoside.

References

1. Charles A. Osunla, Anthony I. Okoh, *Vibrio* Pathogens: A Public Health Concern in Rural Water Resources in Sub-Saharan Africa, *Int J Environ Res Public Health*. 2017; **14**(10): 1188. DOI: 10.3390/ijerph14101188.
2. Michael H. Bross, Kathleen Soch, Robert Morales, Rayford B. Mitchell, *Vibrio vulnificus* Infection: Diagnosis and Treatment, *Am Fam Physician*. 2007; **76**(4): 539-544.
3. Yan-Chiao Mao, Po-Yu Liu, Dong-Zong Hung, Wei-Cheng Lai, Shih-Ting Huang, et al, Bacteriology of *Naja atra* Snakebite Wound and Its Implications for Antibiotic Therapy, *Am J Trop Med Hyg*. 2016; **94**(5): 1129-1135. DOI: 10.4269/ajtmh.15-0667.
4. Fredrick M. Abrahamian, Ellie J.C. Goldstein, Microbiology of Animal Bite Wound Infections, *Clinical Microbiology Reviews*. 2011; **24**(2): 231-246. DOI: 10.1128/CMR.00041-10.

5. M Wagener, M Naidoo, C Aldous, Wound infection secondary to snakebite, *South African Medical Journal*. 2017; **107**(4): 315-319. DOI: 10.7196/SAMJ.2017.v107i4.12084.
6. Piyasiri DLB. Sepsis and wound infection following snakebite; a review including the Sri Lankan perspective, *Sri Lanka College of Microbiologists Bulletin*. 2014; **12**(1): 37-39. Available from: <https://slmicrobiology.lk/slcm-bulletins/>
7. Mitrakrishnan Chrishan Shivanthan, Jevon Yudhishdran, Rayno Navinan, Senaka Rajapakse, Hump-nosed viper bite: an important but under-recognized cause of systemic envenoming. *Journal of Venomous Animals and Toxins Including Tropical Diseases*. 2014; **20**: 24. DOI: 10.1186/1678-9199-20-24.